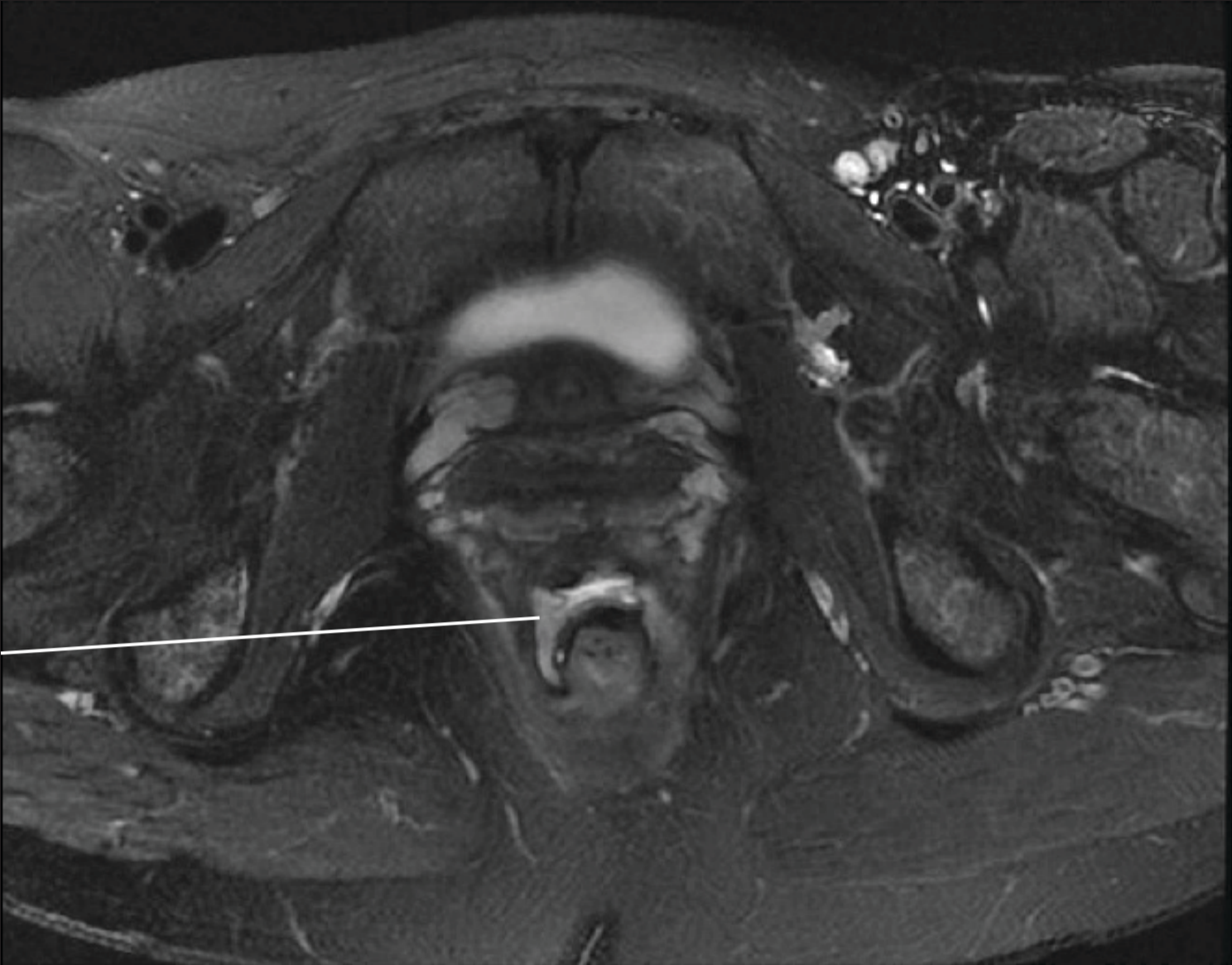
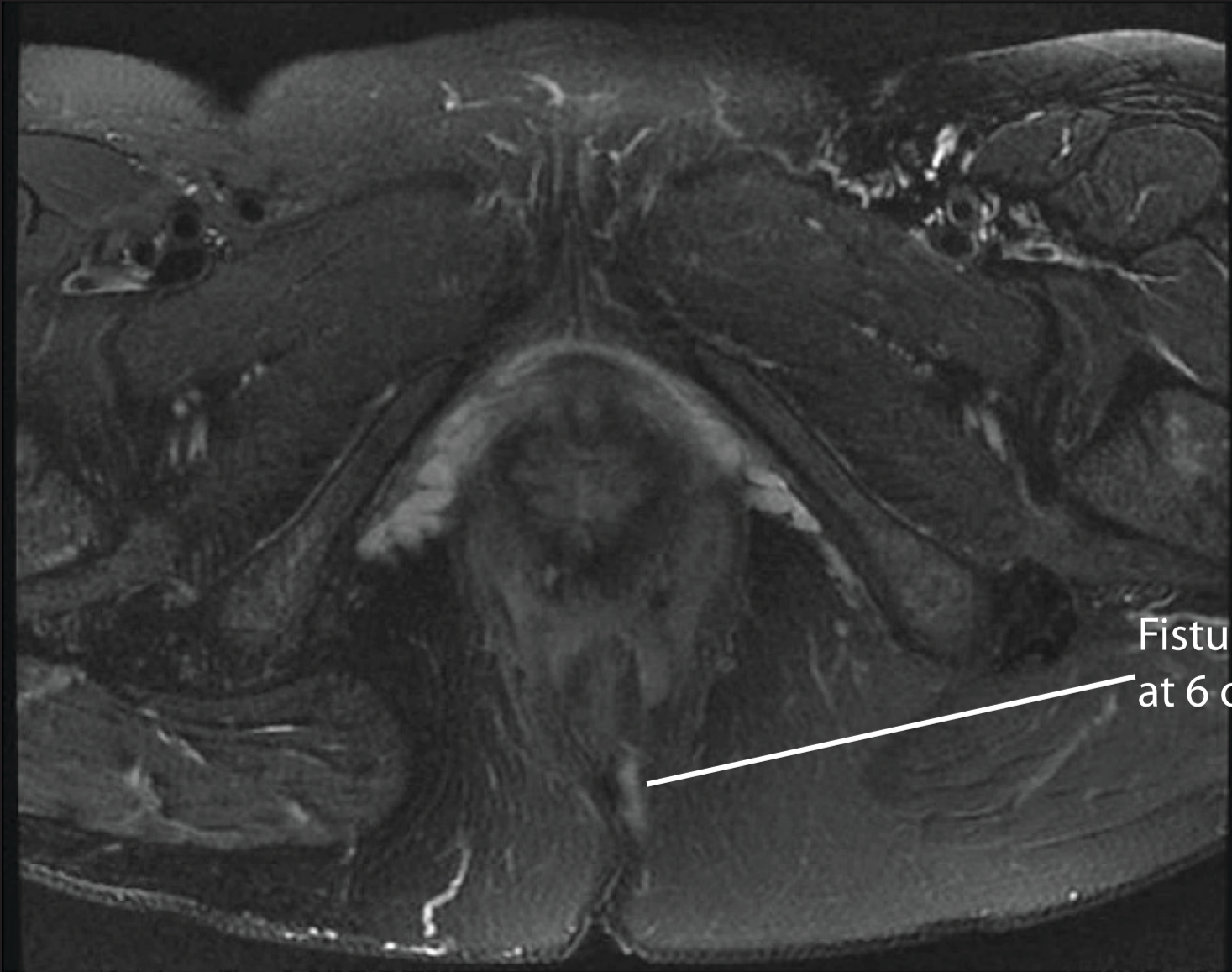


Axial MR scans demonstrating a fistula in ano
(T2 weighted images with fat suppression to improve conspicuity
of high signal track against background)



Intersphincteric
collection



Fistula track opening
at 6 o'clock